

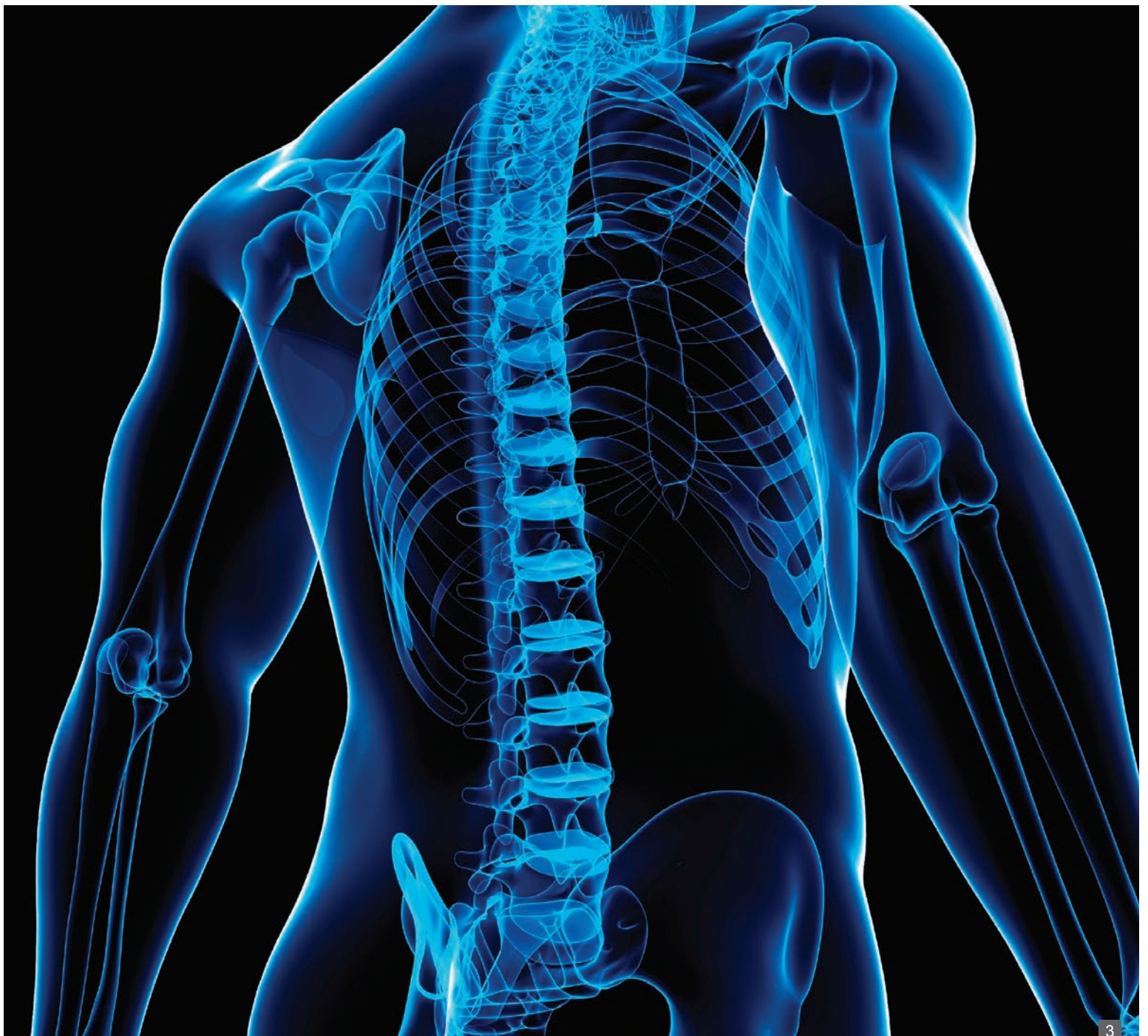
ABSTRACTS ON CLINICAL USE OF MISONIX BONE SCALPEL™



Bone Removal with Misonix BoneScalpel™ in Surgery of the Spine	3 - 16
Surgical Video Portfolio: Spine	17
Bone Removal with Misonix BoneScalpel™ in Surgery of Head & Neck	19 - 25

Bone Removal with Misonix BoneScalpel™ in Surgery of the Spine	Blood Loss Reduced During Surgical Correction of AIS with an Ultrasonic Bone Scalpel	4
	Applications of the Ultrasonic Bone Cutter in Spinal Surgery - Our Preliminary Experience	6
	Safety of Spinal Decompression Using an Ultrasonic Bone Curette Compared with a High-speed Drill: Outcomes in 337 Patients	7
	Use of an Ultrasonic Osteotome Device in Spine Surgery: Experience From the First 128 Patients	8
	Osteotomy for Laminoplasty without Soft Tissue Penetration, Performed Using a Harmonic Bone Scalpel: Instrumentation and Technique	10
	Ultrasonic Bone Scalpel for Osteoplastic Laminoplasty in the Resection of Intradural Spinal Pathology: Case Series and Technical Note	11
	Use of Ultrasonic Bonescalpel In Spine Surgeries: Experience from the First 58 Patients	12
	Minimally Invasive Cervical Elastic Laminoplasty - Principles and Surgical Technique	13
	Laboratory Study: Safety And Efficacy of a Novel Ultrasonic Osteotome Device in an Ovine Model	14
	Use of a Novel Ultrasonic Bone Scalpel for Osteoplastic Laminoplasty in the Resection of Intradural Spinal Cord Pathology	15
Technical Note: A Novel Bone-Cutting Instrument, the Bonescalpel™, May Be Useful in Performing Osteoplastic Laminoplasty	16	
Surgical Video Portfolio: Spine	Cervical Spine – Anterior, Cervical Spine - Posterior, Lumbar Spine, Sacrum & Pelvis	17
Bone Removal with Misonix BoneScalpel™ in Surgery of Head & Neck	Novel Use of an Ultrasonic Bone-cutting Device for Endoscopic-Assisted Craniosynostosis Surgery	20
	Ultrasonic Orthognathic Surgery: Enhancements to Established Osteotomies	21
	Piezoelectric Bonescalpel Osteotomies in Osteocutaneous Free Flaps	22
	Use of Ultrasonic Straight Blade in Orthognathic Surgery: Review of 75 Patients	23
	Use of Ultrasonic Straight Blade in Orthognathic Surgery	24
	Complex Facial Reconstruction By Osteoinduction: the First Ever Clinical Application of the Vastus Intermedius Perforator Periosteal Flap (Vipp) and Facial Skeletal Transplantation Without Immunosuppression	25

Bone Removal with Misonix BoneScalpel™ Ultrasonic Osteotome in Surgery of the Spine



Blood Loss Reduced During Surgical Correction of AIS with an Ultrasonic Bone Scalpel

Carrie E. Bartley, MA; Tracey P. Bastrom, MA; Peter O. Newton, MD

20th International Meeting on Advanced Spine Techniques (IMAST), Vancouver, Canada, July 2013.

Abstract

Summary

Using an ultrasonic bone scalpel to perform facetectomies and Ponte osteotomies when surgically treating AIS resulted in significantly less EBL than cuts made with standard osteotomes and rongeurs.

Introduction

Recently an ultrasonic powered bone cutting device has come onto the market with approval for use in the spine. Because the unit efficiently cuts bone, but spares soft tissues, it can be used to perform facetectomies (both inferior and superior articular process) and Ponte osteotomies in place of using standard osteotomes and rongeurs. We began using this device and perceived a reduction in bone bleeding associated with cut boney surfaces

Purpose

The purpose of this study was to evaluate the blood loss in adolescent idiopathic scoliosis (AIS) cases with and without the use of the bone scalpel to perform posterior Ponte releases.

Method

Single surgeon's cases. 60 Adolescent Idiopathic Scoliosis patients treated with Posterior Spinal Fusion. 20 Bone Scalpel Group (Surgeon's first 20 cases). 2 control groups, 20 Most Recent cases prior to surgeon using bone scalpel, 20 Cobb Matched cases from prior to surgeon using bone scalpel. All patients underwent a Ponte release. Patients who underwent an anterior procedure were excluded. ANOVA was used to compare patient demographic and surgical info in the bone scalpel group to each control group.

Results

No differences were found between the Bone Scalpel group and either control group in terms of age, Cobb, # levels fused, # levels released (Ponte osteotomies), or surgical time.

	BoneScalpel	Most Recent Controls	p-value	Cobb Matched Controls	p-value
Age (yrs)	15 ± 3	14 ± 2	0.671	14 ± 2	0.227
Thoracic Cobb (deg)	53 ± 9.5	51 ± 12	0.508	54 ± 9.6	0.869
Lumbar Cobb (deg)	38 ± 12	33 ± 14	0.251	35 ± 13	0.445
# of Levels Fused	11.5 ± 1.1	11.0 ± 2.0	0.547	11.3 ± 1.3	0.589
# Levels Released	5.5 ± 1.1	5.2 ± 1.6	0.499	5.5 ± 1.2	0.90
Surgical Time (min)	247 ± 62	233 ± 42	0.41	229 ± 30	0.25

The bone scalpel group had significantly less blood loss than both the most recent and Cobb matched control groups.

	BoneScalpel	Most Recent Controls	p-value	Cobb Matched Controls	p-value
EBL (cc)	550 ± 359	799 ± 376	0.039	886 ± 383	0.007
Cell Saver Transfused (cc)	94 ± 146	184 ± 122	0.042	198 ± 115	0.017
EBL/Levels Fused (cc)	48 ± 30	72 ± 28	0.01	78 ± 30	0.003
EBL/Levels Released (cc)	100 ± 50	163 ± 71	0.003	178 ± 30	0.009

Conclusion

The use of an ultrasonic bone scalpel to perform the bone cuts associated with facetectomies (both inferior and superior articular processes) and Ponte osteotomies results in significantly less bleeding compared to cuts made with standard osteotomes and rongeurs. With the use of the bone scalpel, the cut surfaces of the bone were “sealed” limiting overall blood loss by 30-40% as compared to the control groups.

Applications of the Ultrasonic Bone Cutter in Spinal Surgery - Our Preliminary Experience

Al-Mahfoudh R, Qattan E, Ellenbogen JR, Wilby M, Barrett C, Pigott T.

Department of Neurosurgery, The Walton Centre for Neurology and Neurosurgery NHS Trust , Liverpool , UK.

Br J Neurosurg. 2013 Jul 10. [Epub ahead of print]

Abstract

Objective

To present our experience with the Misonix Ultrasonic Bone scalpel in spinal surgery, highlighting its potential applications and advantages.

Methods

Between March and December 2011, a total of 937 spinal cases were performed at a single centre. The Misonix Bone Scalpel (MBS) was used in 62 of these cases. Data were collected prospectively using the Spine Tango registry. Patient demographics, disease type, surgery performed and complications were all recorded along with pre- and post-operative core measures outcome index (COMI).

Results

The majority of cases were for spinal degenerative disorders, in particular, revision cases. The bone cutter was also used to achieve laminotomies for access to intradural tumours, corpectomies and a mixture of other pathologies. Of the 62 patients only 1 (1.6%) experienced a blood loss greater than 500 ml, and there was only 1 dural tear (1.6%) as a direct result of the MBS. Four illustrative cases are discussed.

Conclusions

The MBS is a useful adjunct in spinal surgery with particular value in revision cases where scar tissue distorts the normal anatomy. There was a low complication rate with a trend to reduced blood loss. This was most apparent to the senior authors during cervical and thoracic corpectomies.

Safety of Spinal Decompression Using an Ultrasonic Bone Curette Compared with a High-speed Drill: Outcomes in 337 Patients

Bydon M, Xu R, Papademetriou K, Sciubba DM, Wolinsky JP, Witham TF, Gokaslan ZL, Jallo G, Bydon A.

Department of Neurosurgery, Johns Hopkins Hospital, Baltimore, Maryland, USA.

J Neurosurg Spine. 2013 Jun;18(6):627-33. doi: 10.3171/2013.2.SPINE12879. Epub 2013 Apr 5.

Abstract

Objective

Unintended durotomies are a common complication of spine surgery and are often correlated with increased postoperative morbidity. Recently, ultrasonic bone curettes have been introduced in spine surgery as a possible alternative to the conventional high-speed drill, offering the potential for greater bone-cutting precision and less damage to surrounding soft tissues. To date, however, few studies have investigated the safety and efficacy of the ultrasonic bone curette in reducing the rates of incidental durotomy compared with the high-speed drill.

Methods

The authors retrospectively reviewed the records of 337 consecutive patients who underwent posterior cervical or thoracic decompression at a single institution between January 2009 and September 2011. Preoperative pathologies, the location and extent of spinal decompression, and the use of an ultrasonic bone curette versus the high-speed drill were noted. The rates of incidental durotomy, as well as hospital length of stay (LOS) and perioperative outcomes, were compared between patients who were treated using the ultrasonic bone curette and those treated using a high-speed drill.

Results

Among 88 patients who were treated using an ultrasonic bone curette and 249 who were treated using a high-speed drill, 5 (5.7%) and 9 (3.6%) patients had an unintentional durotomy, respectively. This finding was not statistically significant ($p = 0.40$). No patients in either cohort experienced statistically higher rates of perioperative complications, although patients treated using an ultrasonic bone curette tended to have a longer hospital LOS. This difference may be attributed to the fact that this series contained a statistically higher number of metastatic tumor cases ($p < 0.0001$) in the ultrasonic bone curette cohort, likely increasing the LOS for that patient population. In 13 patients, the dural defect was repaired intraoperatively. No patients who experienced an incidental durotomy had new-onset or permanent neurological deficits postoperatively.

Conclusions

The safety and efficacy of ultrasonic bone curettes in spine surgery has not been well established. This study shows that the ultrasonic bone curette has a similar safety profile compared with the high-speed drill, although both are capable of causing iatrogenic dural tears during spine surgery.

Use of an Ultrasonic Osteotome Device in Spine Surgery: Experience From the First 128 Patients

Hu X, Ohnmeiss DD, Lieberman IH.

Scoliosis and Spine Tumor Center, Texas Back Institute, Texas Health Presbyterian Hospital Plano, Plano, TX, USA

Eur Spine J. 2013 Apr 16. [Epub ahead of print]

Abstract

Introduction

The ultrasonic BoneScalpel is a tissue-specific device that allows the surgeon to make precise osteotomies while protecting collateral or adjacent soft tissue structures. The device is comprised of a blunt ultrasonic blade that oscillates at over 22,500 cycles/s with an imperceptible microscopic amplitude. The recurring impacts pulverize the noncompliant crystalline structure resulting in a precise cut. The more compliant adjacent soft tissue is not affected by the ultrasonic oscillation. The purpose of this study is to report the experience and safety of using this ultrasonic osteotome device in a variety of spine surgeries.

Methods

Data were retrospectively collected from medical charts and surgical reports for each surgery in which the ultrasonic scalpel was used to perform any type of osteotomy (facetectomy, laminotomy, laminectomy, en bloc resection, Smith Petersen osteotomy, pedicle subtraction osteotomy, etc.). The majority of patients had spinal stenosis, degenerative or adolescent scoliosis, pseudoarthrosis, adjacent segment degeneration, and spondylolisthesis et al. Intra-operative complications were also recorded.

Results

A total of 128 consecutive patients (73 female, 55 male) beginning with our first case experience were included in this study. The mean age of the patients was 58 years (range 12-85 years). Eighty patients (62.5 %) had previous spine surgery and/or spinal deformity. The ultrasonic scalpel was used at all levels of the spine and the average levels operated on each patient were 5. The mean operation time (skin to skin) was 4.3 h and the mean blood loss was 425.4 ml. In all cases, the ultrasonic scalpel was used to create the needed osteotomies to facilitate the surgical procedure without any percussion on the spinal column or injury to the underlying nerves. There was a noticeable absence of bleeding from the cut end of the bone consistent with the ultrasonic application. There were 11 instances of dural injuries (8.6 %) and two of which were directly associated with the use of ultrasonic device. In no procedure was the use of the ultrasonic scalpel abandoned for use of another instrument due to difficulty in using the device or failure to achieve the desired osteotomy.

Conclusions

Overall, the ultrasonic scalpel was safe and performed as desired when used as a bone cutting device to facilitate osteotomies in a variety of spine surgeries. However, caution should be taken to avoid potential thermal injury and dural tear. If used properly, this device may decrease the risk of soft tissue injury associated with the use of high speed burrs and oscillating saws during spine surgery.

Primary Diagnosis	Cases
Spinal stenosis	24
Degenerative scoliosis	15
Pseudoarthrosis	15
Adjacent segment degeneration	11
Idiopathic scoliosis	11
Degenerative spondylolisthesis	10
Disc herniation	9
Flat back syndrome	7
Metastatic spine tumor	5
Vertebral compression fracture	3
Congenital scoliosis	2
Kyphosis	2
Loosened hardware	2
Sacral fracture	2
Scheuermann's kyphosis	2
Spinal spondylosis	2
Spinal tumor	2
Multiple myeloma	1
Vertebral sarcoma	1
Epidural hematoma	1
Pseudoarticulation	1
Total cases	128

Table 1. The primary diagnosis of the ultrasonic BoneScalpel cases.

Osteotomy for Laminoplasty without Soft Tissue Penetration, Performed Using a Harmonic Bone Scalpel: Instrumentation and Technique

Nickele C, Hanna A, Baskaya MK

Department of Neurological Surgery, University of Wisconsin Hospital and Clinics, Madison, Wisconsin, USA

J Neurol Surg A Cent Eur Neurosurg. 2013 Mar 15; DOI <http://dx.doi.org/10.1055/s-0032-1328958>

[Epub ahead of print]

Abstract

Background

Laminoplasty in the case of intramedullary spinal tumor requires care to avoid neurologic injury. The harmonic bone scalpel provides a method of laminoplasty that can be done safely and quickly for this and other indications.

Patients

Five cases are presented, each of which required operative intervention, namely laminoplasty. The pathologies presented are one cervical intramedullary tumor, one thoracic intramedullary spinal mass, one lumbar extramedullary intradural tumor, and two cases of multiple lower brachial plexus nerve root avulsions requiring dorsal root entry zone (DREZ) lesion.

Results

These five patients underwent laminoplasty for either tumor resection or DREZ lesion. The laminotomies were performed using the BoneScalpel™ (Misonix Inc., Farmingdale, NY, USA), which is a harmonic bone scalpel instrument. This obviated the need to place any instrument under the intact lamina. Kerrison punches and various instruments were still used, but for purposes other than the bony removal of the laminoplasty.

Conclusion

These cases demonstrate that the BoneScalpel™ can be used to facilitate the laminar cuts while still allowing a safe and effective operation, even in cases as delicate as an intramedullary thoracic spinal cord tumor. The mechanism of action of the harmonic bone scalpel allows osteotomies without cutting or penetrating soft tissue and also leaves minimal bony defect.

Ultrasonic Bone Scalpel for Osteoplastic Laminoplasty in the Resection of Intradural Spinal Pathology: Case Series and Technical Note

Parker SL¹, Kretzer RM², Recinos PF^{2,3}, Molina CA², Wolinsky JP², Jallo GI², Recinos VR³.

¹ Department of Neurosurgery, Vanderbilt University Medical Center, Nashville, Tennessee

² Department of Neurosurgery, The Johns Hopkins University School of Medicine, Baltimore, Maryland

³ Department of Neurosurgery, Cleveland Clinic, Cleveland, Ohio.

Neurosurgery. 2012 Dec 20. [Epub ahead of print]

Abstract

Background

Osteoplastic laminoplasty is a well-described technique that may decrease the incidence of progressive kyphosis when used in the setting of intradural spinal cord tumor resection.

Objective

The BoneScalpel™ by Aesculap is an ultrasonic osteotome that precisely cuts bone while preserving the underlying soft tissues, potentially reducing the risk of dural laceration during laminoplasty. By producing osteotomies as narrow as 0.5 mm, the device may also facilitate post-operative osteointegration.

Methods

A retrospective analysis was conducted of 40 patients (mean age: 38.0 years, range: 4.0-79.7 years) who underwent osteoplastic laminoplasty using the BoneScalpel™ for the treatment of intradural spinal pathology at the Johns Hopkins Hospital between January 2009 and December 2011. Following lesion resection, titanium plates were used to reconstruct the lamina in all cases. The technical results and procedure-related complications were subsequently noted.

Results

Successful laminoplasty was carried out in all 40 cases. Intraoperatively, one case of incidental durotomy was noted following use of the device, which was repaired primarily without neurological or clinical sequelae. During the follow-up period (mean: 195 days, median: 144 days), there were 2 complications (CSF leak=1, seroma=1) and no cases of immediate post-operative instability.

Conclusion

The BoneScalpel™ by Aesculap is a safe and technically feasible device for performing osteoplastic laminoplasty.

Note: The Misonix BoneScalpel™ is manufactured and distributed worldwide by Misonix, Inc., Farmingdale, NY, USA. Aesculap, Inc., USA, acts as a private label distributor for Misonix to selected customers in the United States for certain disposable products, limited to spinal and cranial clinical applications.

Use of Ultrasonic BoneScalpel in Spine Surgeries: Experience from the First 58 Patients

Isador H. Lieberman, MD, MBA, FRCSC; Xiaobang Hu, PhD

Scoliosis and Spine Tumor Center, Texas Back Institute, Plano, TX, USA

19th International Meeting on Advanced Spine Techniques (IMAST), Istanbul, Turkey, July, 2012

Abstract

Summary

We retrospectively reviewed 58 consecutive patients who underwent spine surgeries with the use of the ultrasonic BoneScalpel. The operation time, blood loss and intraoperative complications were recorded. In all instances the BoneScalpel was able to efficiently create the needed osteotomies to facilitate the surgical procedure without any percussion on the spinal column or injury to the underlying nerves.

Introduction

The ultrasonic BoneScalpel is a tissue specific device that allows the surgeon to make precise osteotomies while protecting collateral or adjacent soft tissue structures. The device is comprised of a blunt ultrasonic blade that oscillates at over 23,000 cycles per second with an imperceptible microscopic amplitude. The recurring impacts pulverize the non-compliant crystalline structure resulting in a precise cut. The more compliant adjacent soft tissue is not affected by the ultrasonic oscillation.

Methods

Data were retrospectively collected following each surgery in which the BoneScalpel was used to perform any manner of osteotomy (facetectomy, laminotomy, etc.). The majority of patients had degenerative or adolescent scoliosis, kyphosis, spinal stenosis and spondylolisthesis.

Results

There were 35 females and 23 males with average age of 61 years (range 14-85). Forty-two patients (72%) had previous spine surgery and/or spinal deformity. The ultrasonic BoneScalpel was used at all levels of the spine and the average operated levels were 5. The mean operation time was 4 hours and the mean blood loss was 360 ml. In all instances the BoneScalpel was able to efficiently create the needed osteotomies to facilitate the surgical procedure without any percussion on the spinal column or injury to the underlying nerves. There was a noticeable absence of bleeding from the cut end of the bone consistent with the ultrasonic application. There was one instance of a 3 mm dural thermal injury which resulted from the overheating of the local tissue by the BoneScalpel blade sitting in one position. This was over-sewn in a water-tight closure. No other intra-operative complications directly related to the BoneScalpel were encountered. With increasing experience, more complex osteotomies were successfully created.

Conclusions

The BoneScalpel is a safe and effective ultrasonic bone cutting device that can be used to facilitate osteotomies in a variety of spine surgeries. This device may obviate the risk associated with the use of high speed burrs and oscillating saws during spine surgery.

Minimally Invasive Cervical Elastic Laminoplasty - Principles and Surgical Technique

P. SUCHOMEL¹, J. HRADIL²

¹ Oddělení Neurochirurgie, Krajská nemocnice Liberec, a. s.

² Ústav zdravotnických studií, Technická Univerzita Liberec

Acta Chir Orthop Traumatol Cech. 2011;78(5):437-41

Abstract

Purpose Of The Study

To present a new technique of minimally invasive decompression of the cervical spinal canal using elastic and plastic deformation of the laminae.

Material And Methods

Short midline vertical incision provides an access to the superior aspect of the target spinous processes. Cranial edge of the lamina is located by a midline, muscle-sparing interspinous dissection. The spinous process is cut in mid-sagittal plane using a thin blade of an ultrasonic bone scalpel down to epidural space. The created sagittal cleavage of the spinous process is subjected to tension and elastic distraction by a custom-designed distractor (Aesculap, Germany). Gradual increase of the distraction force leads to a significant plastic deformation. This reduces the distraction force and allows for a wider exposure which, in turn, facilitates dural visualization, resection of the yellow ligament and undercutting of approximately a half of the adjacent intact laminae. After completion of decompression, the plastic arch expansion can be maintained either by interposed bone-graft or appropriately shaped cage secured by a circumferential suture to the spinous process. Soft tissue resection and permanent expansion of the laminae provide sufficient decompression of the cervical spinal cord. In multilevel stenosis, the desired laminae can be expanded using this technique. To achieve the same degree of canal expansion as that by a classic laminoplasty (C3-7), a skip technique

can be utilized. This involves combining expansive laminoplasty of C4 and C6 with bilateral undercutting of C5 and partial undercutting of C3 and C7. This can be achieved through two short vertical incisions. Based on data and experience gained from testing on 11 cadavers, we applied this method in 7 patients requiring posterior cervical decompression.

Results

The spinous process or laminae fractured during expansion in the initial 4 patients and the procedure required conversion to a minimally invasive laminectomy. Further modification of the distractor and spinous process splitting technique resulted in elimination of this complication in subsequent cases. In all remaining patients, sufficient canal expansion was achieved by soft tissue resection and distraction of laminae, typically reaching 5 - 8 mm. Minimally-invasive muscle-sparing midline approach provided very positive functional results in terms of postoperative pain and range of motion allowing for immediate mobilization without external bracing.

Conclusion

Minimally invasive, muscle sparing, expansive laminoplasty provides adequate spinal canal expansion. Use of this technique and its muscle-sparing nature potentially result in improvement of early functional outcomes when compared to standard laminoplasty techniques requiring lateral lamina-facet border exposure. However, the theoretical superiority of this technique will need to be clinically scrutinized in a well designed surgical outcome study.

Laboratory Study: Safety and Efficacy of a Novel Ultrasonic Osteotome Device in an Ovine model

Matthew R. Sanborn^{a*}, Jeffrey Balzer^b, Peter C. Gerszten^b, Patricia Karausky^b, Boyle C. Cheng^b, William C. Welch^a

^a Department of Neurosurgery, University of Pennsylvania, 3400 Spruce St., 3 Silverstein Building, Hospital of the University of Pennsylvania, Philadelphia, PA 19104, USA

^b Department of Neurological Surgery, University of Pittsburgh, Pittsburgh, PA, USA

Journal of Clinical Neuroscience 18 (2011) 1528–1533

Abstract

The use of ultrasonic technology for bone removal offers the potential advantages over the use of traditional hand instruments or cutting burrs of more precise bone resection and reduced soft-tissue injury. While the use of modified ultrasonic aspirators has been described for bone removal in spinal surgery, none of these instruments has been systematically examined to evaluate safety and efficacy. Thus, we compared laminectomies using traditional instruments, and traditional instruments with an ultrasonic osteotome, in an ovine model. We used a combination of clinical examination, intra-operative and post-operative neuromonitoring and histological

analysis to evaluate safety. The secondary endpoint of efficiency was assessed by examining operative times. No significant difference was found between groups in neurophysiology or the Tarlov clinical rating scale. Histology revealed inflammatory or reparative changes in 6/8 experimental animals and 2/4 control animals with a single section in an experimental animal revealing focal nerve root disruption and mild axonal loss. A single durotomy was noted in both the control and experimental groups. Operative time for the experimental group was significantly shorter than the operative time for the control group.

Use of a Novel Ultrasonic Bone Scalpel for Osteoplastic Laminoplasty in the Resection of Intradural Spinal Cord Pathology

Scott L. Parker BS; Ryan M. Kretzer MD; Pablo F. Recinos MD; George I. Jallo MD; Violette Renard Recinos MD

Department of Neurosurgery, The Johns Hopkins University School of Medicine, Baltimore MD

Department of Neurosurgery, The Cleveland Clinic, Cleveland, OH

27th Annual Meeting of the AANS/CNS Section on Disorders and Peripheral Nerves, Phoenix, AZ, March 2011

Abstract

Introduction

Osteoplastic laminoplasty is a well described alternative to laminectomy in the treatment of spinal pathology. Recent studies have shown that laminoplasty may decrease the incidence of progressive kyphotic deformity when used in the setting of intradural spinal cord tumor resection, especially in the pediatric population. A novel device, the BoneScalpel™ by Aesculap, is an ultrasonic osteotome that precisely cuts bone while preserving the underlying soft tissues. In the case of laminoplasty, this potentially reduces the risk of dural laceration. In addition, the device allows for fine osteotomies as narrow as 0.5 mm, which may facilitate better post-operative bone healing.

Methods

We present our experience with 11 patients who underwent osteoplastic laminoplasty using the BoneScalpel™ in the setting of intradural pathology between January 2009 and September 2010. Following lesion resection, titanium plates were used to reconstruct the lamina. The technical advantages and procedure-related complications of using an ultrasonic bone osteotome in the resection of intradural spinal cord lesions were analyzed.

Results

Successful laminoplasty was carried out in all 11 cases. One case of incidental durotomy was noted following use of the device, which was repaired primarily without neurological or clinical sequelae. There were no cases of peri-operative complications such as wound infection or CSF leak. There was also no incidence of immediate post-operative spinal instability.

Conclusions

The BoneScalpel™ by Aesculap is a safe and technically feasible device for performing osteoplastic laminoplasty. It allows for a narrower laminar trough to be created than conventional drilling, which may lead to improved laminar healing and prevent delayed post-laminectomy kyphosis. Further studies and longer clinical follow-up are needed to delineate the true role of this device in the treatment of spinal cord pathology.

Note: The Misonix BoneScalpel™ is manufactured and distributed worldwide by Misonix, Inc., Farmingdale, NY, USA. Aesculap, Inc., USA, acts as a private label distributor for Misonix to selected customers in the United States for certain disposable products, limited to spinal and cranial clinical applications.

Technical Note: A Novel Bone-Cutting Instrument, the BoneScalpel™, May be Useful in Performing Osteoplastic Laminoplasty

Violette Renard Recinos, MD, Edward Ahn, MD, Benjamin Carson, MD, George Jallo, MD

Department of Neurosurgery, The Johns Hopkins University School of Medicine, Baltimore, Maryland

AANS/CNS Section on Pediatric Neurological Surgery Annual Meeting, Boston, MA, December 2009.

<http://www.aans.org/Media/Article.aspx?ArticleId=63641>

Abstract

Introduction

Laminoplasty is a well described alternative to laminectomy in the treatment of spinal pathology. Recent studies have shown that laminoplasty used for pediatric intramedullary spinal cord tumor resection may decrease the incidence of progressive spinal deformity. A novel device, the BoneScalpel™ by Aesculap, is an ultrasonic osteotome that allows the surgeon to cut the bone while preserving the underlying soft tissue, potentially reducing the risk of dural laceration. In addition, it allows for very fine cuts as narrow as 0.5 mm. We used the BoneScalpel™ to perform osteoplastic laminoplasties in 2 patients undergoing surgery for spinal cord tumors and describe our preliminary findings.

Methods

Two patients who were undergoing planned laminoplasty for spinal cord tumors were brought to the OR and standard exposure of the appropriate lamina was carried out. In order to perform the laminoplasty, the BoneScalpel™, was used to cut troughs on either side of the lamina. The cut lamina were then disconnected rostrally and caudally from the posterior spinal ligament, and removed as one unit. Once the tumor resection was completed and dura closed, the bone was replaced with small bone plating systems.

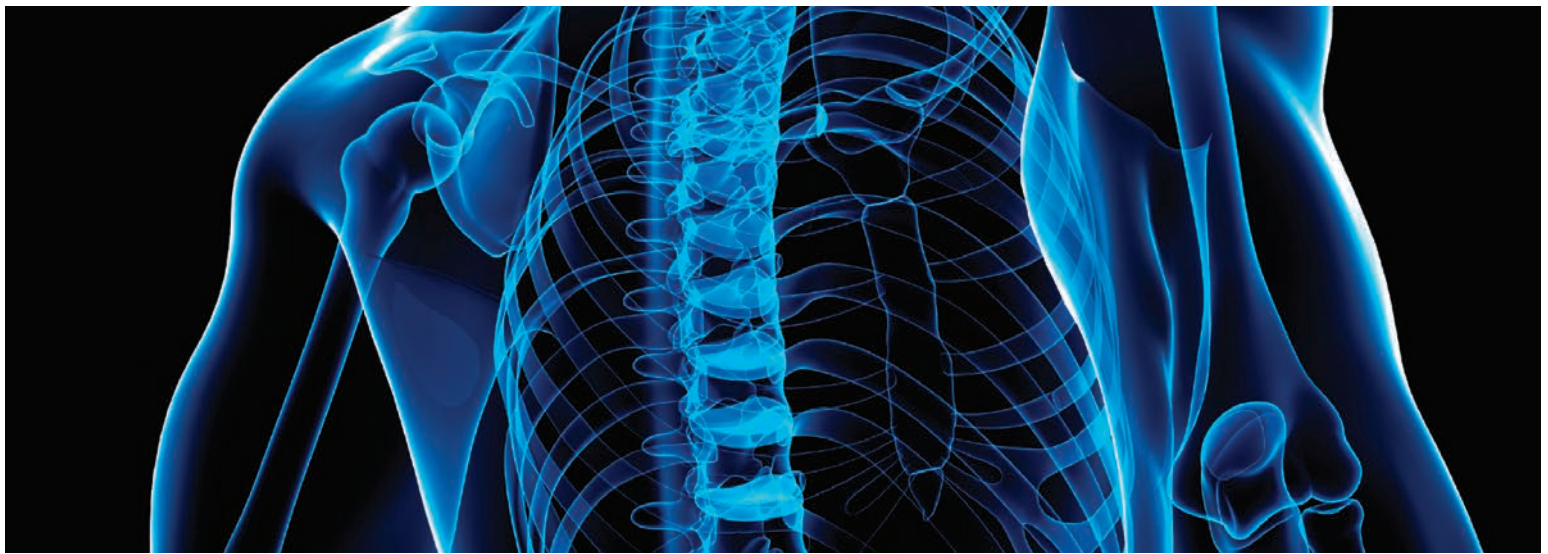
Results

Successful laminoplasty was carried out in both cases. No known damage to the underlying soft tissue, dura or neural elements was identified.

Conclusions

The BoneScalpel™ by Aesculap is a potentially useful and safe device in performing osteoplastic laminoplasty. As it allows for a more narrow trough than conventional drilling, less bone is ultimately removed. This could be especially useful in the pediatric population where the smaller defect in the approximated bone may lead to improved healing. Further studies should be carried out to explore this as a potential option.

Note: The Misonix BoneScalpel™ is manufactured and distributed worldwide by Misonix, Inc., Farmingdale, NY, USA. Aesculap, Inc., USA, acts as a private label distributor for Misonix to selected customers in the United States for certain disposable products, limited to spinal and cranial clinical applications.



Surgical Video Portfolio: Spine

Cervical Spine - Anterior

[Anterior Cervical Corpectomy](#) **PLAY**

Peyman Pakzaban, MD,
Houston MicroNeurosurgery, Houston, TX

[Anterior Cervical Discectomy and Fusion \(ACDF\)](#)

Uwe Hassepass, MD, Pforzheim, Germany **PLAY**

[Anterior Cervical Foraminotomy during ACDF \(Shaver\)](#) **PLAY**

Uwe Hassepass, MD, Pforzheim, Germany

[Anterior Cervical Foraminotomy during ACDF \(Blade\)](#) **PLAY**

Peyman Pakzaban, MD,
Houston MicroNeurosurgery, Houston, TX

[Iliac Crest Harvest for ACDF](#) **PLAY**

Uwe Hassepass, MD, Pforzheim, Germany

Cervical Spine - Posterior

[Cervical Laminoplasty](#) **PLAY**

Peyman Pakzaban, MD,
Houston MicroNeurosurgery, Houston, TX

[Suboccipital Craniotomy](#) **PLAY**

Peyman Pakzaban, MD,
Houston MicroNeurosurgery, Houston, TX

Lumbar Spine

[Lumbar Laminectomy for Intradural Tumor](#) **PLAY**

Peyman Pakzaban, MD,
Houston MicroNeurosurgery, Houston, TX

[Lumbar Hemilaminectomy](#) **PLAY**

Peyman Pakzaban, MD,
Houston MicroNeurosurgery, Houston, TX

[Lumbar Laminotomy and Sequestrectomy](#) **PLAY**

Uwe Hassepass, MD, Pforzheim, Germany

[Lumbar Decompression with Undercutting](#) **PLAY**

Uwe Hassepass, MD, Pforzheim, Germany

[Interlaminar Approach for Lumbar Decompression](#) **PLAY**

Uwe Hassepass, MD, Pforzheim, Germany

[Lumbar Facetectomy for TLIF](#) **PLAY**

Peyman Pakzaban, MD,
Houston MicroNeurosurgery, Houston, TX

[Lumbar Endplate Osteophyte Resection for TLIF](#) **PLAY**

Peyman Pakzaban, MD,
Houston MicroNeurosurgery, Houston, TX

[Lumbar Revision Surgery](#) **PLAY**

Uwe Hassepass, MD, Pforzheim, Germany

Thoracic Spine

[Thoracic Facetectomy for Deformity](#) **PLAY**

Peter Newton,
Rady Children's Hospital, San Diego, CA

[Thoracoplasty](#) **PLAY**

Suken Shah, MD, Nemours/Alfred I.
DuPont Hospital for Children, Wilmington, DE

Sacrum & Pelvis

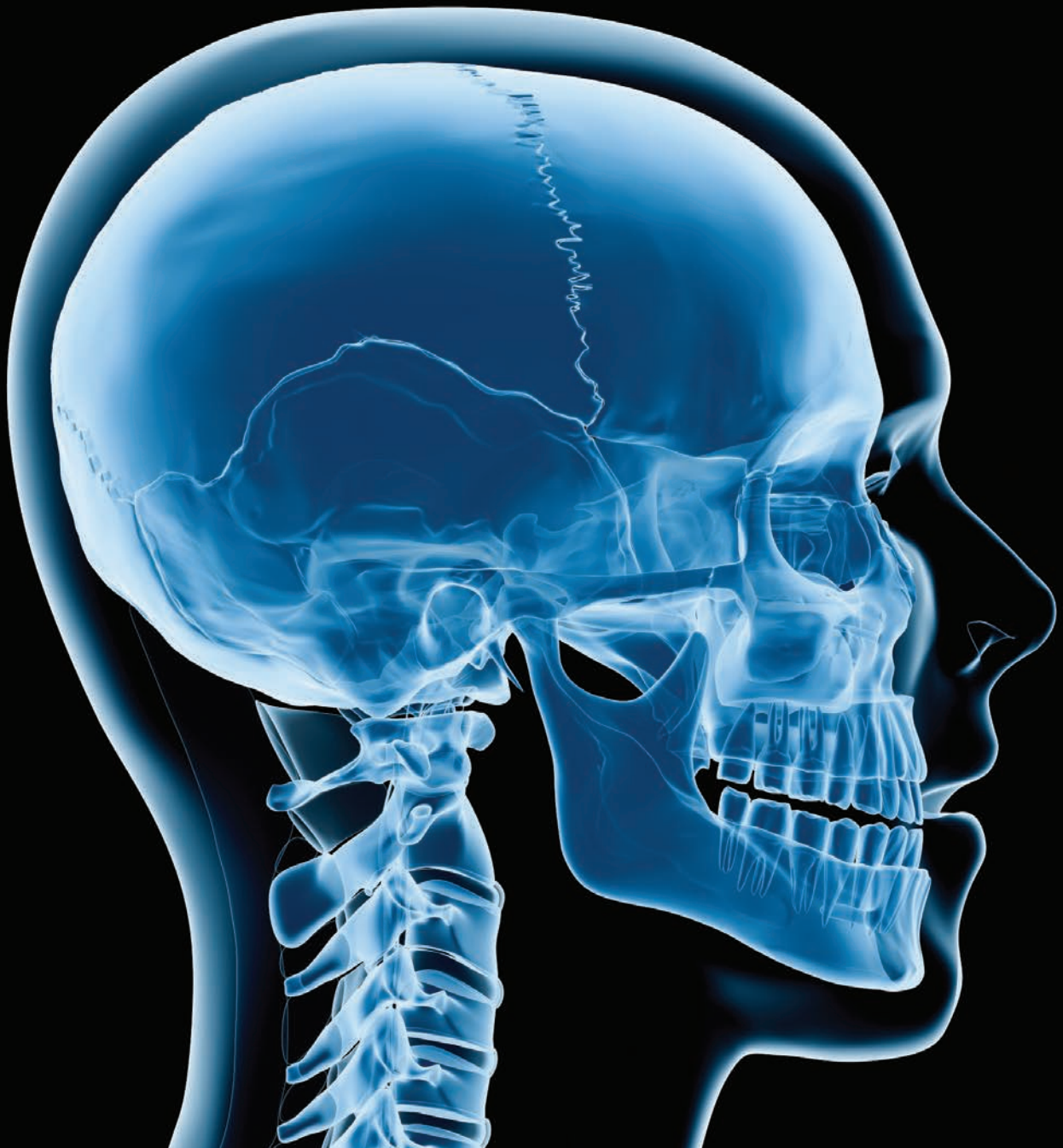[Sacral Cyst Removal](#) **PLAY**

Uwe Hassepass, MD, Pforzheim, Germany

[Iliac Crest Harvest for ACDF](#) **PLAY**

Uwe Hassepass, MD, Pforzheim, Germany

Bone Removal with Misonix BoneScalpel™ Ultrasonic Osteotome in Surgery of Head & Neck



Novel Use of an Ultrasonic Bone-cutting Device for Endoscopic-Assisted Craniosynostosis Surgery

Chaichana KL, Jallo GI, Dorafshar AH, Ahn ES

Division of Pediatric Neurosurgery, Johns Hopkins University School of Medicine, Baltimore, MD, USA

Childs Nerv Syst. 2013 Feb 6; DOI 10.1007/s00381-013-2043-6. [Epub ahead of print]

Abstract

Purpose

Endoscopic-assisted craniosynostosis surgery is associated with less blood loss and shorter operative times as compared to open surgery. However, in infants who have low circulating blood volumes, the endoscopic approach is still associated with significant blood loss. A major source of blood loss is the bone that is cut during surgery. We discuss the novel use of an ultrasonic bone-cutting device for craniosynostosis surgery, which decreases bone bleeding. This device, which has primarily only been used for spine and skull base surgery, may help reduce blood loss in these infants.

Methods

All patients with single suture craniosynostosis who were operated on with the use of an ultrasonic bone-cutting device were identified. The information retrospectively recorded from patient charts included patient age, suture involved, blood loss, operative times, complications, preoperative hemoglobin, postoperative hemoglobin, length of hospital stay, and follow-up times.

Results

Thirteen patients (12 males, 1 female) underwent surgery with an ultrasonic bone-cutting device during the reviewed period. The average age (\pm standard deviation) of the patients was 11.8 (\pm 1.6) weeks. Four patients had metopic synostosis and nine patients had sagittal synostosis. The average surgery time was 84 (\pm 13) min. The median (interquartile range) blood loss was 20 (10-70) cc. No patients required blood transfusions. Three patients had dural tears.

Conclusion

We demonstrate the novel use of an ultrasonic bone-cutting device for endoscopic-assisted craniosynostosis surgery. This device limited blood loss while maintaining short operative times for infants with low circulating blood volumes.

Ultrasonic Orthognathic Surgery: Enhancements to Established Osteotomies

R. Gilles¹, T. Couvreur², S. Dammous³

¹ Department of Oral and Maxillofacial Surgery, ² Department of Radiology, ³ Department of Oral and Maxillofacial Surgery, Clinique de Espérance, Belgium

Int. J. Oral Maxillofac. Surg. 2012; xxx:xxx–xxx; <http://dx.doi.org/10.1016/j.ijom.2012.12.004>, available online at <http://www.sciencedirect.com>

Accepted 5 December 2012, published online 10 January 2013.

Abstract

The use of a novel ultrasonic osteotome enabled the authors to modify well-established orthognathic osteotomies to more favourably address the anatomy. For this purpose, they utilized a powerful ultrasonic device with tissue-selective cutting characteristics that was originally developed for spinal osteotomies and nerve decompression (BoneScalpel™ by Misonix Inc., Farmingdale, NY, USA). Its straight ultrasonic blade was adapted for dual action, and a soft protective element was added. The product modifications and the related changes regarding maxillary and mandibular osteotomies are explained in detail. A series of 83 patients underwent

orthognathic surgery with the BoneScalpel ultrasonic osteotome. All osteotomies within this study group were performed purely ultrasonically and without the auxiliary use of reciprocating saws or rotary burrs. The complications, alveolar nerve impairment and bad splits were assessed. To assess the quality of the lingual osteotomies and pterygomaxillary separation, three-dimensional scanning was performed on 30 patients. In conclusion, the BoneScalpel™ ultrasonic osteotome enabled improved control over orthognathic osteotomies and resulted in significant reductions in the occurrence of nerve impairment and bad splits.

Piezoelectric Bonescalpel Osteotomies in Osteocutaneous Free Flaps

Wick, C. C., Rezaee, R. P. and Zender, C. A. (2012),

Department of Otolaryngology–Head and Neck Surgery, University Hospitals Ear, Nose, and Throat Institute; University Hospitals Case Medical Center, Cleveland, Ohio, U.S.A.

The Laryngoscope. doi: 10.1002/lary.23740

Abstract

Objectives

A novel utilization of a piezoelectric device in the harvesting of osteocutaneous free flaps.

Materials and Method

Nonrandomized case series assessing a new osteotomy device, the Misonix BoneScalpel™ Ultrasonic Osteotome. Five patients underwent mandibular resections related to oncologic disease of the head and neck at University Hospitals Case Medical Center. The mandibular defects were reconstructed with osteocutaneous free flaps: three fibular, one radial forearm, and one scapular. Patients were managed per institutional protocol for head and neck free flaps. The BoneScalpel™ was used for all harvesting and reconstructive osteotomies. The two lead surgeons recorded subjective operative feedback.

Results

All osteotomies were successfully created. The lead surgeons (R.P.R and C.A.Z.) report improved tactile control, minimal learning curve, and similar operative time compared to traditional oscillating and reciprocating saws. Vascular pedicles and adjacent soft tissue were not damaged. Bony unions appeared clinically intact at 7-month follow-up.

Conclusion

The BoneScalpel™ Ultrasonic Osteotome offers a safe and efficient method for osteotomies during the harvest of osteocutaneous free flaps. Advantages include better tactile control, more precise osteotomies, minimal learning curve, and theoretic protection of vital soft tissue structures. Future studies with objective data are needed to further support this novel technique in head and neck reconstruction.

† This manuscript was presented as a poster presentation for AAFPRS at the Combined Otolaryngology Spring Meetings (COSM) in San Diego, CA, on April 18–19, 2012.

‡ The authors have no funding, financial relationships, or conflicts of interest to disclose.

Use of Ultrasonic Straight Blade in Orthognathic Surgery: Review of 75 Patients

S. Dammous, R. Gilles

CHC Liege. Liege. Belgium

International Journal of Oral and Maxillofacial Surgery, Volume 40, Issue 10, 2011, 1082

Abstract

Purpose

Piezoelectric osteotomies have been limited in the field of orthognathics due to unfavorable tip angulations and insufficient cutting power for mandibular cuts. By adapting its ultrasonic blades and protective elements we have hence modified a more powerful ultrasonic (BoneScalpel™. Misonix, Inc., Farmingdale, NY, USA).

Patients and methods

75 patients underwent orthognathic surgery with the ultrasonic BoneScalpel. All osteotomies in the group were solely being performed with the ultrasonic straight blade without use of saw or burr at any time. Effects of peri-operative bleeding, post-operative edema, operative time and osseous consolidation were assessed.

Results and conclusions

An absence of nerve lesions was observed as well as significant reductions in swelling, hematoma, operative time and hospital stay. A delay in osseous consolidation was non-evident. The absence of bleeding facilitates osteotomy of the posterior wall of the maxilla and the pterygo-maxilla junction. Improved safety in the pterygomaxillary zone facilitates the down-fracture. Sagittal split is eased which is attributed to the propagation of the ultrasonic wave into the cancellous layer. Moreover, the osseous cutting is more precise and allows for an improved adaption to the anatomy e.g. in older patients (SAOS) or in cases of asymmetry. We noted an increase in referrals and submissions since we started using this less traumatic technique. We conclude the ultrasonic straight blade facilitates the procedures of orthognathic surgery.

Conflict of interest

None declared

Use of Ultrasonic Straight Blade in Orthognathic Surgery

R. Gilles, S. Dammous

CHC Liege - Belgium

Journal of Oral and Maxillofacial Surgery, Volume 69, Issue 9, Supplement, 2011, e23

Abstract

Statement of the Problem

Piezoelectric osteotomies have been limited in the field of orthognathics due to unfavorable tip angulations and insufficient cutting power for mandibular cuts. By adapting its ultrasonic blades and protective elements we have hence modified a more powerful ultrasonic (BoneScalpel™, Misonix, Inc., Farmingdale, NY). The system was originally developed for spinal osteotomies and operates as a constant, non-modulated ultrasonic frequency of 22.5 kHz. The novel dual-action blade is of straight configuration. Its blunt distal edge enables deep insertions up to 20mm into the bone, unilateral serrations provide for long lateral osteotomies. All procedures within this study group were solely being performed with the ultrasonic BoneScalpel and without use of reciprocating saws or rotary burrs.

Materials and Methods

50 patients underwent orthognathic surgery with the ultrasonic BoneScalpel: 42 for Lefort I osteotomy, 56 for sagittal split, 6 for symphyseal osteotomy and 1 for advancement genioplasty.

Methods of Data Analysis

Operation time and length of hospital stay were evaluated objectively. Soft tissue edema was clinically evaluated in a subjective manner. Outpatient follow-up was done after 15 days, 2 months, 6 months and 1 year. Patients were interviewed for presence of paresthesia, dysesthesia and for affected skin areas. Functional results and osseous consolidations were clinically and radiologically evaluated at the same meetings.

Results and Investigation

An absence of nerve lesions was observed as well as reductions in swelling, hematoma, operative time and hospital stay. Not a single dental lesion was evident. The reduction in bleeding facilitates particularly osteotomies of the maxilla and posterior osteotomies become safe and risk free. Sagittal splits are facilitated, which is attributed to the propagation of the ultrasonic oscillation into the cancellous layer. Moreover, the osseous cutting is more precise and allows for an improved adaption to the anatomy. A delay in osseous consolidation was non-evident. All osteotomies in the group were performed with the ultrasonic BoneScalpel and it was not necessary to return to traditional power instruments like saw or burr at any time.

Conclusion

Recent improvements in ultrasonic surgery proved beneficial for Orthognathic surgery. Described advantages are reductions in bleeding and post-operative edema, absence of nerve lesions, nasal mucosal preservation and improved ability to adapt the osteotomy technique to the anatomy eg, in older patients (SAOS) or in cases of asymmetry. In addition, one retains a significant reduction in operative time. Improved safety in the pterygomaxillary zone facilitates the down-fracture and the sagittal split is eased by the propagation of the ultrasonic wave into the cancellous layer. We also noted an increase in referrals and submissions since we started using this less traumatic technique. We conclude that the use of an ultrasonic straight blade facilitates the procedures.

Complex Facial Reconstruction by Osteoinduction: The First Ever Clinical Application of the Vastus Intermedius Perforator Periosteal Flap (VIPP) and Facial Skeletal Transplantation Without Immunosuppression

Rian Adam Maercks, MD and Eric SantaMaria

2nd Biannual Meeting of the American Society for Reconstructive Transplantation, Chicago, IL, November 2010.

Abstract

Background

The published Vastus Intermedius Periosteal Flap (VIPP) includes the entire periosteum of the femur dependent on the descending branch of the lateral circumflex femoral artery. A less bulky flap with reduced dissection can be harvested based on consistent musculoperiosteal perforators at the junction of the middle and distal thirds of the thigh. We report the first clinical application of the Vastus Intermedius Periosteal (VIPP) flap and provide video documentation of its vascularity.

Methods

A patient bone loss of the superior orbital bar, frontal region and temporal process of the zygoma was treated with the VIPP flap. An ALT skin paddle was dissected, four musculoperiosteal perforators were identified and dissected to periosteum and 80% of the circumference of the femoral periosteum was harvested. A thin 8 x 2 cm piece of femoral cortex was included. The vascularized bony frame replaced the orbital rim and the vascularized periosteum was placed over the remainder of the bony defect. A vascular anastomosis was performed between the pedicle and the superficial temporal vessels.

Results

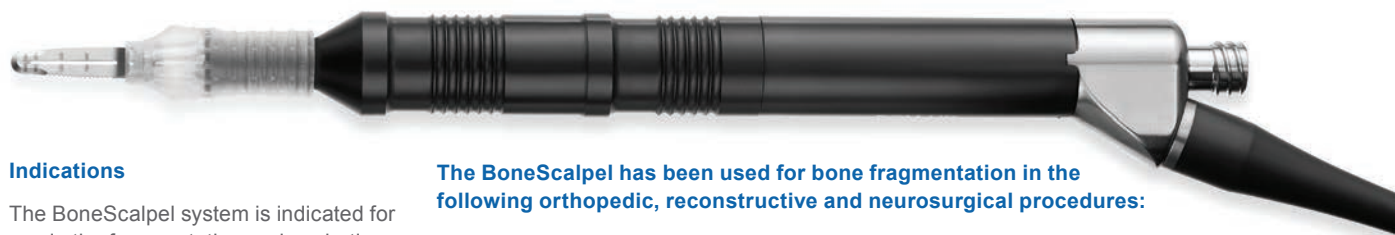The first ever VIPP flap was confirmed to have a robust vascularity. Its chimeric nature allowed easy monitoring of the skin paddle. Video documentation demonstrates that skin, muscle, periosteum and cortical bone bleed briskly when elevated with the pedicle. The flap suffered two hematomas on days 2 and 5 which required evacuation and evaluation in the operating room. On day 7 the skin paddle was excised. Periosteal flap and osseous construct were left in place.

Conclusions

We confirm vascularity of the VIPP flap for osteoinduction. Computed tomography evaluation of osteogenesis is shortly pending. This flap allows consideration of a new technique of reconstructive transplantation, osseous transplant without immunosuppression. Long bone periosteum is osteoinductive and capable of replacing large masses of bone. Using a VIPP flap, a processed cadaveric segment of facial skeleton can precisely restore human form with the patient's own cellular machinery. This technique may be the ultimate answer to complex facial skeletal reconstructions until the science and art of facial transplantation becomes widely applicable. We are initiating a series of reconstructions with specific facial skeletal allograft and VIPP flap.

Note: A novel ultrasonic osteotome (Misonix BoneScalpel) was used to resect the femoral periosteum of the VIPP flap.

BoneScalpel™ Ultrasonic Osteotome



Indications

The BoneScalpel system is indicated for use in the fragmentation and aspiration of both soft and hard (e.g.: bone) tissue as used in the following surgical specialties:

- Orthopedic Surgery
- Plastic and Reconstructive Surgery
- Neurosurgery
- Thoracic Surgery
- Wound Care
- General Surgery

It is also indicated for use in debridement of wounds, such as, but not limited to burn wounds, diabetic ulcers, bedsores and vaginal ulcers, soft tissue debridement and cleansing of the surgical site in application, in which, in the physician's judgment would require the use of an ultrasonic aspirator with sharp debridement.

CAUTION: Federal law restricts this device to sale by or on the order of a licensed healthcare practitioner

Contra Indications

The BoneScalpel system is contra indicated for cardiac surgery and any procedure in the proximity of the heart.

The irrigation pump is contra indicated for the administration of parenteral fluids, infusion of drugs or for any life sustaining purposes

The BoneScalpel is manufactured and distributed by Misonix, Inc., Farmingdale, NY, USA.

The BoneScalpel has been used for bone fragmentation in the following orthopedic, reconstructive and neurosurgical procedures:

Thoraco-Lumbar

- Laminectomy
- Laminotomy
- Foraminotomy
- Sacral laminoplasty
- Decompression of spinal canal (ipsi-lateral, contra-lateral by undercutting)
- Decompression in revision cases
- Sequestrectomy
- Facetectomy
- Transforaminal lumbar interbody fusion
- Thoracic corpectomy

Cervical

- Laminectomy
- Laminoplasty
- Foraminotomy
- Osteophyte resection
- Resection of osteochondrosis
- Robinson-Smith procedure
- Anterior corpectomy
- Anterior foraminotomy
- Intra-oral dens resection

Spinal Deformity

- Facetectomy
- Ponte osteotomy
- Smith Peterson osteotomy
- Pedicle subtraction osteotomy
- Vertebral column resection
- Thoracoplasty

Minimally Invasive Spine

- Microscopic approach
- Approach through MIS retractor (e.g. METRx)
- Thoracoscopic approach (not cleared in the U.S.)

Maxilla

- Maxillary osteotomy
- Maxillary corticotomy
- Maxillectomy, hemi-max.
- LeFort I osteotomy
- Exostosis excision
- Sinus lift

Mandible

- Mandibular osteotomy
- Mandibular corticotomy
- Mandibulectomy
- Sagittal split osteotomy
- Sagittal osteotomy
- Mandibular Decortication
- Genioplasty

Skull Base and Cranial

- Suboccipital craniotomy
- Orbital-zygomatic craniotomy
- Craniotomy for orbital tumors
- Orbital reconstruction
- Correction of craniosynostosis

Pediatrics

- Pediatric craniotomy
- Pediatric craniosynostosis
- Pediatric sternotomy in revision

Oncology

- Bone tumor resection

Reconstructive Surgery

- Bone harvest from fibula, iliac crest, chin, and parietal
- Maxillary and mandibular reconstruction
- Orbital reconstruction
- Vastus intermedius perforator periosteal flap (VIPPP) for complex facial reconstruction
- Osteo-periosteal flap for revascularisation of femoral head (hip necrosis)





1938 NEW HIGHWAY, FARMINGDALE, N.Y. 11735 | +1.631.694.9555 +1.631.694.3285 FAX

Misonix® is a registered trademark of Misonix, Inc., Farmingdale, NY. BoneScalpel™ is a pending trademark of Misonix, Inc., Farmingdale, NY
© 2013 Misonix, Inc. All rights reserved. Printed in the USA, BS-1301 Rev B