



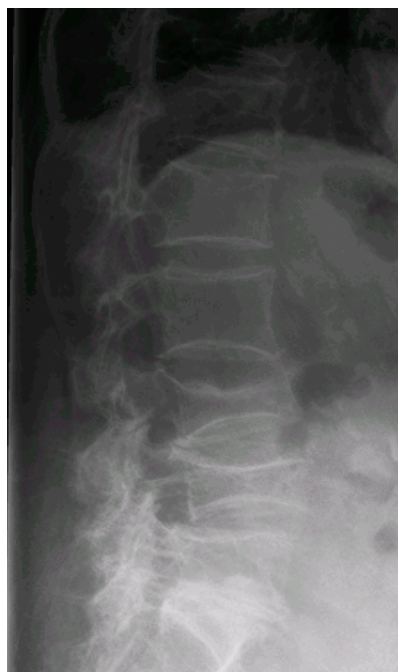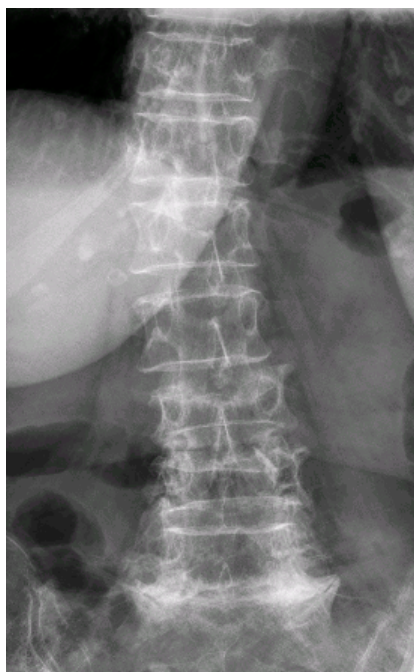
“Case of month”

Clinical information:

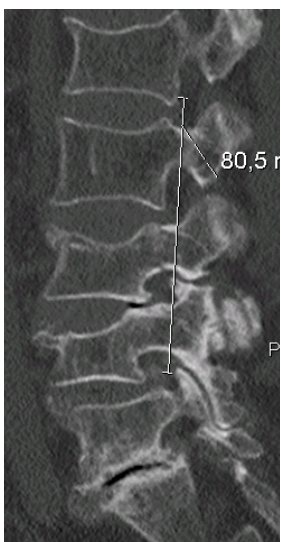
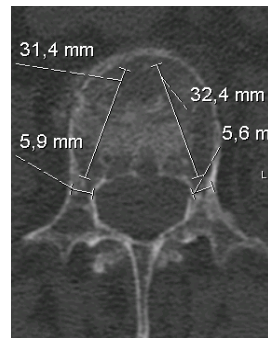
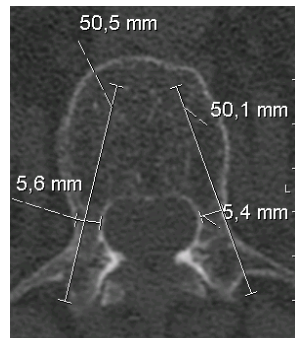
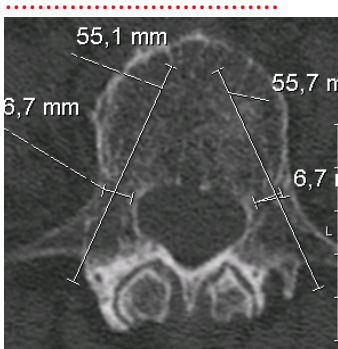
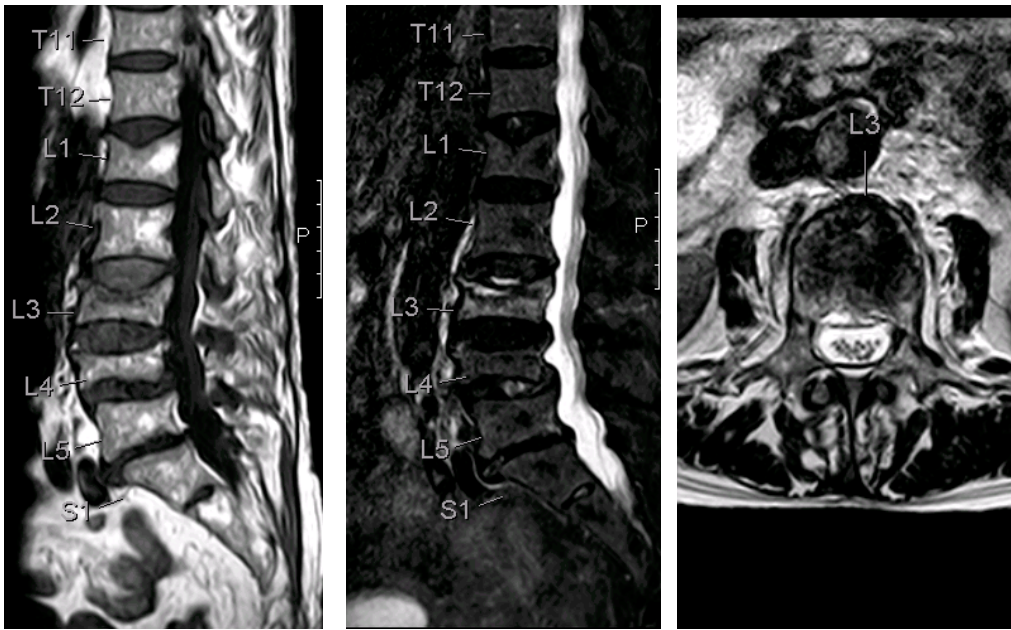
- Light carrying trauma
- 85 Y, F,
- T 11
- VAS preop 8 post op 2
- Pronounced Osteoporosis
- Duration of the procedure for Tektona alone: 25 Minutes
- Zement volume right side 2.3 ml, left 2.1 ml
- In-patient stay 7 days (with internal fixator)
- Discharge after 4 days post op

Radiological:

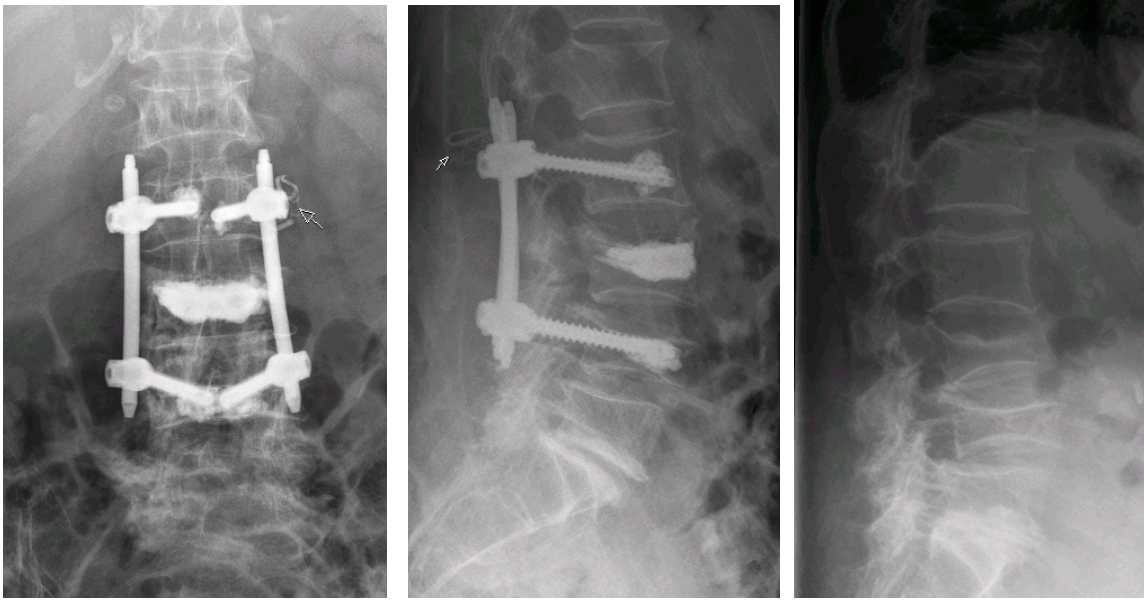
Pre Op X-Ray



MRI Pre Op



Post Op



The Fix. was placed after the Tektona treatment (neutralisation)

Result

Anterior height : 13,1mm

Middle height:10,1mm / 10,2mm

